ORIGINAL ARTICLE

Role of High Resolution Computed Tomography (HCRT) in Evaluation of Pathologies of Temporal Bone

Rajesh Sharma

Abstract

To evaluate role of HRCT in detecting and diagnosing the pathologies and congenital anomalies of the temporal bone. The prospective study was conducted on 40 patients with suspected temporal bone pathologies on Bright Speed Elite 16 CT scanner in the department of Radio-Diagnosis and Imaging in Acharya Shri Chander College of Medical Sciences and Hospital, Sidhra Jammu. Imaging findings were correlated with surgical findings where ever applicable. Temporal bone pathologies were more common in males (65%) with 67.5% in age group 20 to 40 years. Most common temporal bone pathologies were infections (60%), trauma (17.5%) followed by tumours (12.5%). Infection of middle ear was most common pathology encountered 60% in which ossicular erosion was most common (37.5%). Most common inflammatory pathology was cholesteatoma (54.2%) followed by mastoiditis (25%). Peak incidence of trauma was seen in young (20 to 30yrs) males (85.7%) with squamous part being involved in 100% followed by petrous (85.7%) and mastoid part (57.1%). Tumours was third common pathology with 80% of subjects in the age group 40 to 80 yrs Acoustic neuroma was most common (40%) followed by meningioma (20%). HRCT outweighs the conventional modalities of investigations and provides higher spatial resolution and better soft tissue contrast for evaluation of Temporal Bone lesions.

Keywords

Ear ossicles, High Resolution Computed Tomography, Histopathological Diagnosis, Pneumatization, Temporal bone

Introduction

The petrous temporal bone is a complex structure containing the middle and inner ear and various contained structures such as ossicles which are of small size. This challenges the limits of resolution by imaging techniques. Good spatial resolution to allow adequate demonstration of these bony structures in the middle and inner ears has been an important requirement of radiographic equipment for many years. Many imaging modalities are available for the evaluation of these portions of temporal bone, including plain radiographs, angiography, cerebrospinal fluid (CSF) analysis, air and non-ionic contrast cisternography, computed tomography (CT), and magnetic resonance imaging (MRI). However CT and MRI are currently the most widely used techniques and have largely replaced the other modalities. Usually, patients with temporal bone pathology first undergo clinical examination, often with audiology tests. Information obtained this way, when combined with imaging findings, provides an accurate and reliable diagnosis, allows avoiding misinterpretation and ensures appropriate treatment.(1) Conventional radiography has been of value in screening the entire temporal bone. However today the use of conventional radiography is limited to the evaluation of mastoid pneumatization. HRCT has the advantage of producing images with higher contrast and a better spatial resolution. HRCT scans are more accurate in identifying many soft tissue abnormalities and are much less prone to artifacts, they have largely replaced polytomography; there is also less radiation to the lens of the globe with CT scans than with polytomography. (2) HRCT is the investigation of choice in diagnosing and defining the extent of

From The : Department of Radiodiganosis, ASCOMS, Sidra Jammu J&K- India
Correspondence to : Dr Rajesh Sharma, Associate Professor, Department of Radiodiganosis, ASCOMS, Sidra Jammu J&K

cholesteatoma and is helpful for detection of lateral canal fistula, erosions of dural plate, and ossicular erosions.(3-5) CT is often complementary to MRI in evaluating petrous apex pathology and in-differential diagnosis of CPA masses.(6,7) Congenital anomalies and normal variants of temporal bone and detection of intracranial complications are easily assessed using HRCT technique.(8) The purpose of the study is primarily to understand the capability of HRCT in diagnosis and detection of pathologies and congenital anomalies of the temporal bone.

Materials and Methods

The prospective study was conducted on 40 patients with suspected temporal bone pathologies in the Department of Radio-Diagnosis and Imaging in co-ordination with the department of E.N.T. at Acharya Shri Chander College of Medical Sciences and Hospital, Sidhra Jammu. All referred patients were evaluated with High Resolution Computed Tomography (Bright Speed Elite 16) of temporal bones, using axial and coronal slices. For contrast enhancement, a bolus injection of non-ionic agent iohexol (omnipaque) containing 350 mg of iodine per ml was given in the dose of 1.5 ml/kg of body weight. Imaging findings were correlated with surgical findings wherever applicable. Data was analyzed using appropriate statistical methods.

Results

HRCT evaluations of 40 patients with suspected temporal bone pathology were enrolled in the study. The results are enumerated in *Table 1 to11*.

Discussion

HRCT plays an important role in the radiographic assessment of temporal bone and is helpful in diagnosis and treatment of temporal bone diseases.(9,10) Slices in different planes can be obtained by CT and it is possible to understand the complex relationship of anatomical

Table 1. Distribution of Disease

Diseases	No. of Patients	Percentage
Infections	24	60
Trauma	7	17.5
Tumour	5	12.5
Congenital	2	5
Others	2	5

Table 2. Distribution of Cases According to Age and Gender

Age (in years)	No. of Patients	Percentage
0-10	4	10
11-20	9	22.5
21-30	11	27.5
31-40	7	17.5
41-50	5	12.5
51-60	1	2.5
61-70	3	7.5

Sex	No. of Patients	Percentage
MALE	26	65
FEMALE	14	35

Table 3. Distribution of Cases According to Presenting Complaints

S. No.	Clinical features	No. of Patients	Percentage
1.	Hearing Loss	18	45
2.	Ear discharge	7	17.5
3.	Facial nerve weakness	3	7.5
4.	Ear pain	14	35
5.	Tinnitus	7	17.5
6.	Head ache	13	32.5
7.	Fever	9	22.5
8.	Cerebellar signs	2	5
9.	Diplopia	3	7.5

Table 4. HRCT Findings for Different Temporal bone Pathologies

HRCT Findings	No. of cases diagnosed by HRCT	Percentage
Ossicular chain involvement	15	37.5
Temporal bone erosion	12	30
Facial canal involvement	3	7.5
External ear involvement	3	7.5
Inner ear involvement	4	10
Jugular bulb involvement	1	2.5

Table 5. Distribution of Infection (n=24)

Distribution of Infection	No. of Patients	Percentage
Cholesteatoma	13	54.2
Mastoiditis	6	25
Both	5	20.8

Table 6. Showing Extent of the Cholesteatoma

Extent	Total	Percentage
1. Protympanum	8	44.4
2. Mesotympanum	8	44.4
3. Epitympanum	11	61.1
4. Hypotympanum	7	38.9
5. Prussack's space	14	77.8
6. Antrum	11	61.1
7. Mastoid Air cells	5	27.8
8. Sinus tympani	7	38.9
9. Facial recess	7	38.9

Table 7. Comparison Between HRCT and Operative Finding in Infections

CT appearance of studied Patients	No. of patients	No. of patients with similar operative findings
1. Cholesteatoma	18	18
2. Opacification of mastoid air cells	18	5 (6 patients of simple mastoiditis and 7 trauma patients were treated conservatively)
3. Ossicular erosion	13	12
4. Tegmen erosion	3	2
5. Facial canal erosion	3	3
6. Scutum erosion	8	8
7. Carotid canal erosion	1	1

structure . In addition to detailed evaluation of the bony structures it also permits assessment of soft tissue components as well.(11)This present prospective study was carried out on 40 patients with suspected temporal lesions to evaluate role of HRCT in temporal bone lesions in age group of 5 years to 68 years with male to female ratio of 1.86:1.12 Patient with inflammatory pathology formed the largest proportion of our cases with majority males <30 years. While as neoplastic conditions were common in older age group >40 years. The common presenting symptoms in our study were hearing loss, followed by otorhhea, and otalgia. Cholesteatoma a misnomer is not a true neoplasm but sac of stratified squamous epithelium. Choleastatoma found behind the tympanic membrane with no history of otitis media is considered congenital. Acquired choleastatomas are of two types primary arising from pars flacida and secondary arising from pars tensa. It's the most frequent soft tissue in middle ear. In our study all 18 cases were of acquired choleastatomawithPussack's space (14 cases) and epitympanum (11cases) being the common sites in middle ear to be involved followed by antrum (11 cases) and meso/ protympanum (8 cases each). Pre-operative HRCT evaluation of choleastatomacases revealed

Table 8.Comparison of HRCT Findings and Operative Results For Involvement of Ear Ossicles in Cholesteatoma

CT Findings	No. of cases diagnosed by CT	Surgery Findings					
		Not detected		Incus involved		Malleus, Incus and Stapes involved	
		No.	%	No.	%	No.	%
Incus involvement	8	0	0.00	7	87.5	0	0.00
Malleus, Incus and Stapes involved	5	0	0.00	--	--	5	100.00

Table 9: Complications of Cholesteatoma (n=18)

CT Findings	No. of Cases	Percentage (%)
Ossicular destruction	13	72.2
Facial Canal Dehiscence	3	16.7
Tegmen tympani erosion	3	16.7
Mastoid Cortex dehiscence	4	22.2
Carotid canal dehiscence	1	5.6
Dural plate dehiscence	0	0

Table10. Parts of Temporal Bone Fracture with Pattern of Fracture

Part of temporal bone fractured	No. of patient	Percentage
Squamous	7	100
Petrous	6	85.7
Pattern of fracture	**No. of patients**	**Percentage**
Mixed/oblique	4	57.1
Longitudinal	2	28.6
Transverse	1	14.3
astoid	4	57.1
Tympanic	3	42.9
Styloid	0	0

Table 11. Distribution of Neoplasm

Distribution of Neoplasm	No. of Patients	Percentage
1. Acoustic neuroma	2	40
2. Meningioma	1	20
3. Metastasis	1	20
4. Rhabdomyosarcoma	1	20

Fig 1. Left sided Cholesteatoma

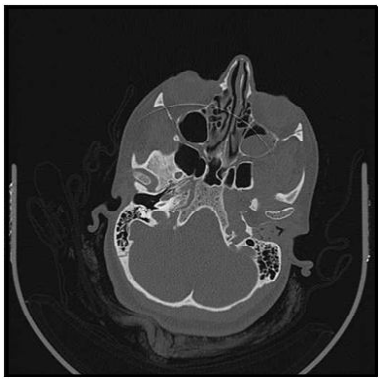

Fig. 2 Left Sided Mastoidtitis

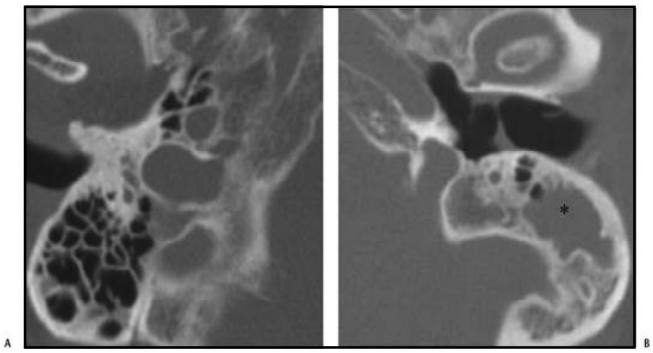

Fig. 3 Right sided Acoustic Neuroma

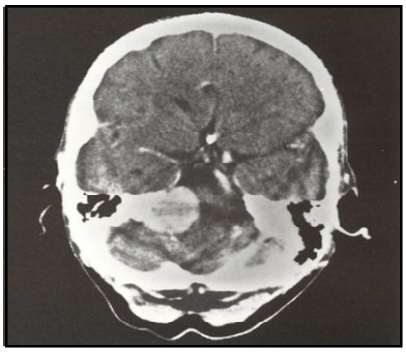

Fig 4. Longitudinal Fracture of Right Temporal Bone

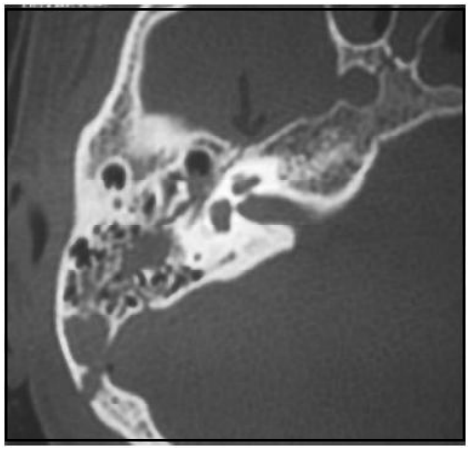

ossicular destruction in 13, followed byscutum erosion (8), facial nerve canal involvement (3), Tegmen (3), carotid canal (1) .Dural plate dehiscence was seen in none of the pateients in our study. Among the ear ossicles involved in choleastatoma incus (8 cases) was the most commonly involved followed by malleus (5 cases). These findings were later correlated with surgical findings that confirmed HRCT findings. Mastoiditis was a common finding in cases of temporal bone pathology and CSOM.(12-13) Trauma to the temporal bone (7cases) was the second most common temporal pathology encountered in our study with males being commonly affected and squamous part (in all 7cases) of temporal bone being commonly fractured followed by petrous (6), mastoid (4), and tympanic part (3 cases). Temporal bone fractures may be oblique, longitudinal or transverse. Oblique fractures were the most common in 4 cases in our study followed by longitudinal (2) and transverse fractures (1).

Ossicular chain disruption is common with longitudinal with incus being commonly dislocated whereas facial nerve injury with palsy of facial nerve and temporomandibular joint is common with transverse fractures.

Neoplastic conditions involved mainly males over 40 years of age with acoustic neuromas being commonest followed by meningioma, metastatic lesion and rhabdomyosarcoma.

In our study both acostic neuromas were extending to internal auditory canal causing it's widening and were invariably detected on HRCT. One cases of CP angle mass was a densely calcified meningioma with no definite extension/destruction of internal auditory canal. One case of metastic lesion from ca breast was detected at petrous apex.

Conclusion

HRCT outweighs the conventional modalities of investigations and provides higher spatial resolution and better soft tissue contrast for evaluation of temporal bone lesions, and is far advantageous in assessing the complications of infection, lays down an anatomical roadmap for the surgeon, predicts certain normal variants of surgical significance preoperatively, identifies the hidden areas of the middle-ear, namely the posterior recesses and depicts the facial nerve anatomy clearly.

References

1. Trojanowska A, Drop A, Trojanowski P et al: "Otitis media with effusion". *Clin Evid.*2006; 15: 814–21.
2. Gerald BB, John BB: "Diseases of temporal bone". Scott Brown's Otolaryngology, 6th edn, 15(3): 1997; 2-7.
3. Shah C, Shah P, Shah S: "Role of HRCT temporal bone in pre operative evaluation of choesteatoma". *Int J Med Sci Public Health* 2014; 3(1): 69-72.
4. Yildirim-Baylan M, Ozmen CA, Gun R et al: "An Evaluation of Preoperative Computed Tomography on Patients with Chronic Otitis Media". *Indian J Otolaryngol Head Neck Surg* 2012; 64(1): 67-70.
5. Rogha M, Hashemi SM, Mokhtarinejad F et al: "Comparison of Preoperative Temporal Bone CT with Intraoperative Findings in Patients with Cholesteatoma". *Iran J Otorhinolaryngol* 2014; 26 (74): 7-12.
6. Isaacson B, Kutz JW, Peter SR: "Lesions of the Petrous Apex,Diagnosis and management". *Otolaryngologic Clinics of North America* 2009; 40(3): 479-519.
7. Fink JR: "Imaging of Cerebellopontine Angle Masses: Self-Assessment Module". *American Journal of Roentgenology* 2010; 195: S15-S21.
8. Phelps PD: "Radiology of ear". Scott Brown's Otolaryngology, 6th Edn, 2(3); 1997: 1-9.
9. Clement P, DeSmedt E. "High resolution tomographic scans of the normal and abnormal ear". *Am J Otolaryngol* 1982; 3: 286-94.
10. Watts S, Flood LM, CliVord K. "A systematic approach to interpretation of computed tomography scans prior to surgery of middle ear cholesteatoma". *J Laryngol Otol* 2000; 114: 248-53.
11. Mafee MF, Kumar A, Vannias DA et al. "Computed tomography of the middle ear in the evaluation of cholesteatomas and other soft tissue masses: Comparison with pluridirectional tomography". *Radiology* 1983; 148: 465-72.
12. Paparella MM, Kim CS. "Mastoidectomy update." *Laryngoscope* 1977; 87: 1977-88.
13. Chole RA, Sudhoff H. "Acute and Chronic Otitis Media and Mastoiditis". Cummings Otolaryngology: Head & Neck Surgery, 2005, 4th edn. 2988-3012.